

## Brain Anatomy, Electrophysiology and Visual Function/Perception in Children within the Autism Spectrum Disorder

**Stephen G. Viola, PhD**

*Affiliate Assistant Professor, University of Missouri-St. Louis; St. Louis, Mo.*

**Dominick M. Maino, OD, MEd, FAAO, FCOVD-A**

*Professor, Illinois College of Optometry; Chicago, Il.*

### ABSTRACT

**Background:** Autism Spectrum Disorders (ASD) affects as many as one in 150 children. These individuals experience significant impairments in social interaction, communication, cognition, and behavioral functioning. Neuroimaging technologies have been utilized during the past twenty years to examine brain anatomy and physiology in individuals with autism to obtain a better understanding of the disorder.

**Methods:** More than seventy-five published articles and papers on the topics of brain anatomy, electrophysiology, and visual function/perception in children with ASD were reviewed. Neurobiological findings include structural abnormalities in the amygdale, hippocampus, corpus callosum, frontal, temporal, and parietal cortex, and the cerebellum. Neurochemistry findings include a wide array of transmitter systems that may contribute to ASD including serotonin, dopamine, acetylcholine, and brain-derived neurotropic factor. There have also been several empirical demonstrations of decreased and enhanced visual abilities of individuals with autism

including abilities in visual acuity, refractive error, pursuits and saccades, and strabismus.

**Conclusions:** Individuals with ASD have numerous neuro-anatomical, neurophysiological, neuropsychological, cognitive and other anomalies that can affect the oculomotor system, vision information processing/visual perception, and the development of refractive error that may require intervention. Optometrists with experience in applying the concepts of behavioral, functional and developmental optometry to patient care should be integral members of the diagnostic and treatment team for individuals with autism.

**Keywords:** autism spectrum disorder, autistic neuroanatomy, autistic visual perception, fMRI studies, oculomotor, optokinetic nystagmus, strabismus, visual evoked potential

### Introduction

First described by Leo Kanner in 1943,<sup>1,2</sup> autism in the early literature was described as a psychiatric disorder caused by parents who did not sufficiently love their children. Although previously believed to be disorders originating in behavior, Autism Spectrum Disorders (ASD) are now generally agreed upon to be complex developmental, neurobiological, and polygenetic disorders that have a broad impact on cognitive and neurological functioning. While ASD is defined and diagnosed by behavioral criteria, the etiology is neurological. In more recent years, studies of ASD have incorporated research on neurobiology and neurochemistry in order to create a more comprehensive understanding of the disorders.

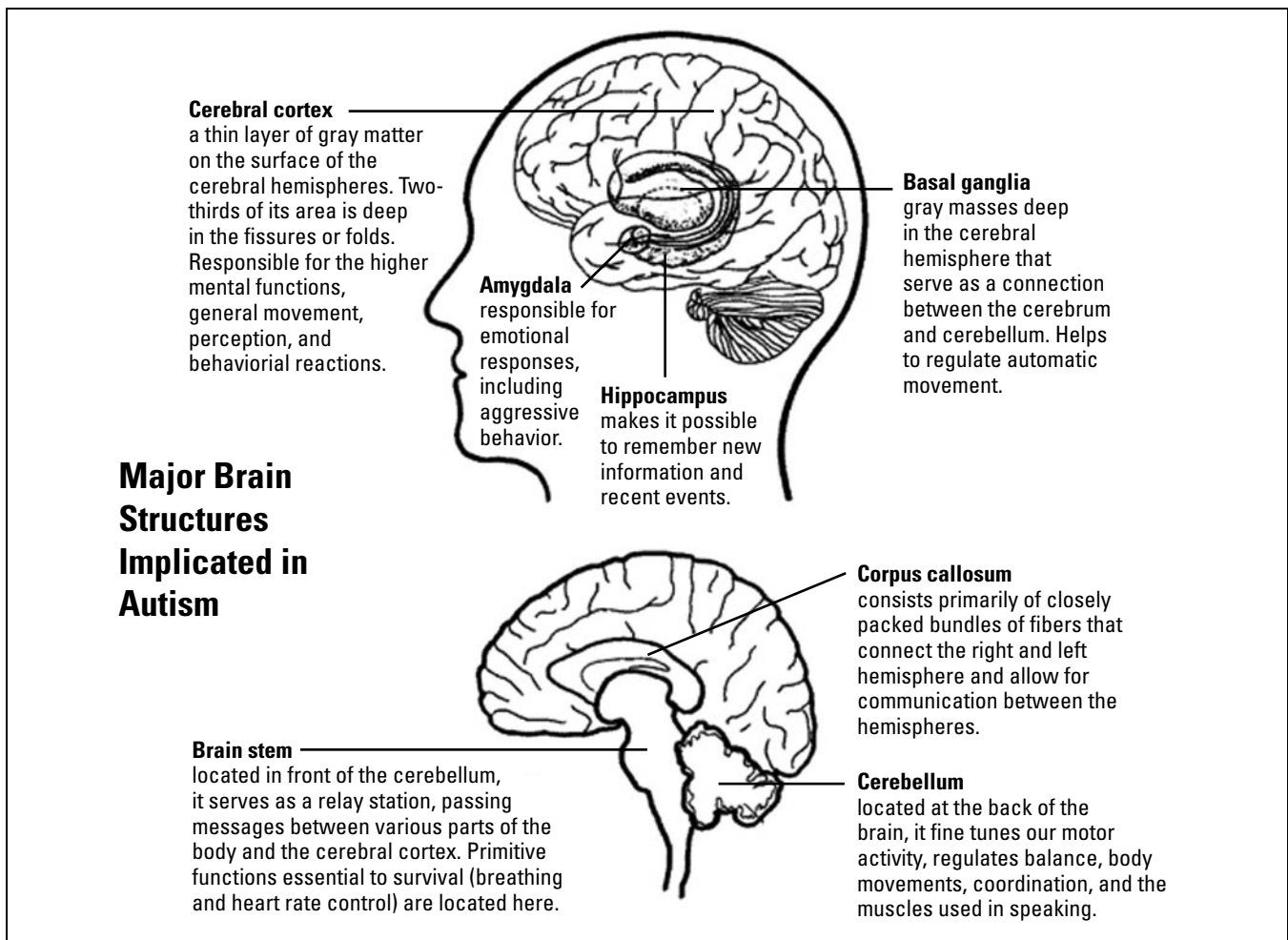
According to 2007 data from the Centers for Disease Control and Prevention,<sup>3</sup> ASD affects as many as one in 150 children and is four times more

---

*Correspondence regarding this article can be emailed to [viola@umsl.edu](mailto:viola@umsl.edu) or sent to Dr. Stephen G. Viola, Affiliate Assistant Professor, University of Missouri-St. Louis, One University Drive, Saint Louis, MO 63121. All statements are the authors' personal opinion and may not reflect the opinions of the College of Optometrists in Vision Development, Optometry & Vision Development or any institution or organization to which the authors may be affiliated. Permission to use reprints of this article must be obtained from the editor. Copyright 2009 College of Optometrists in Vision Development. OVD is indexed in the Directory of Open Access Journals. Online access is available at <http://www.covd.org>.*

Viola SG, Maino DM. Brain anatomy, electrophysiology and visual function/perception in children within the autism spectrum disorder. *Optom Vis Dev* 2009;40(3):157-163.

---



Source: Wikimedia Commons - Authors: National Institutes of Mental Health, National Institutes of Health. This work is in the public domain.

prevalent in males than in females. Individuals with ASD experience significant impairments in social interaction, communication, cognition, and behavioral functioning.<sup>4</sup> They also display restricted, repetitive, and stereotyped patterns of behaviors, interests, and activities.<sup>5</sup> Additional characteristics of autism include failure of language development, lack of eye contact, and minimal curiosity as well as problems with imaginative play and abnormal absorption in repetitive tasks.<sup>6,7</sup>

## Neurobiology

In the past twenty years, neuroimaging technologies have been utilized to examine brain anatomy in individuals with autism in order to identify structural abnormalities. Increased total brain, parieto-temporal lobe, and cerebellar hemisphere volumes are the most replicated abnormalities in autism.<sup>8</sup> Also, research suggests that the size of the amygdale, hippocampus, and corpus callosum may be abnormal as well.<sup>9-11</sup> It is conceivable that abnormalities in neural net-

work involving fronto-temporo-parietal cortex, limbic system, and cerebellum may underlie the pathophysiology of autism, and that such changes could result from abnormal brain development during early life.<sup>12</sup>

Structural magnetic resonance imaging studies originally confirmed the total brain volume increase in autism, originally inferred from increased head circumferences.<sup>13</sup> Because the onset of brain overgrowth in individuals with ASD coincides with the onset of symptoms of autism, it is assumed that the overgrowth is part of a pathological process that disrupts the normal function and structure of the brain.<sup>14,15</sup> Increased fronto-occipital circumference appears to be one of the most consistent neurobiological findings in autism.<sup>16-18</sup> However, Hardan et al. did not find significant difference between autism and normal subjects.<sup>19</sup> Abnormally enlarged volumes of frontal, temporal, and parietal lobes,<sup>20,21</sup> and increased gray matter density in the inferior and middle temporal gyri<sup>9</sup> have been reported in children and adults

with autism. However, there have also been studies indicating signs of superior parietal cortical volume loss<sup>22</sup> and abnormally decreased volumes of right cingulate,<sup>9,23</sup> left occipito-temporal cortex,<sup>21</sup> and left inferior frontal gyrus and decreased grey matter with increased CSF.<sup>1,9</sup> Furthermore, decreased hippocampal measures have been found in juvenile and mostly high-functioning adults with autism.<sup>10,24</sup> However, several other studies have reported no abnormalities in this region.<sup>25,26</sup>

Other structures such as the hippocampus, amygdala, and corpus callosum have recently been suggested to be structurally abnormal in individuals with autism, and possibly implicated in the pathophysiology of the disorders. In regard to the corpus callosum, abnormally reduced anterior, middle, and posterior callosal sub-regions have consistently been reported in individuals with autism, even after controlling for gender and total brain measures.<sup>27,28</sup> Additionally, several studies describe abnormalities in total corpus callosum areas in autism.<sup>27,29</sup> Some studies suggest that the amygdala and hippocampus may be increased.<sup>9,16,26</sup> The hippocampus and amygdala are involved in social learning, cognitive function, and emotional processing<sup>16,31</sup> and might play a role in social behavior and social intelligence deficits in individuals with autism.

A consistent neurological abnormality found in persons with autism is marked Purkinje cell loss in the cerebellum.<sup>22,32,33</sup> The Purkinje cell is an exceptionally large inhibitory neuron in the cerebellum that receives extensive excitatory input from both parallel fibers (from granule cells) and climbing fibers (from the inferior olivary nucleus). Abnormalities in Purkinje cells are behaviorally manifested in difficulties with impulsivity. The current thought in autism is that Purkinje cell loss is not due to cell death, but abnormal development during gestation.

Researchers at the Howard Florey Institute in Australia using fMRI technology have shown that children with autism have less activation in the deep parts of the brain responsible for executive function (attention, reasoning, and problem solving). Specifically, they found that activity in the caudate nucleus, a critical part of circuits that link the prefrontal cortex of the brain, is reduced in boys with autism.<sup>34</sup> These findings have important implications since prefrontal brain circuits play a critical role in maintaining and focusing attention, planning and

setting goals, and keeping goals in memory during problem-solving and decision making.

More recently, research in neurobiology has enabled scientists to move from the simplistic view that was once held to the multifaceted connectivity model that is accepted and developing today. An important finding coming out of functional magnetic resonance imaging studies concerns cortical connectivity. Specifically, a pattern of activation, timing, and synchronization of the activation across the cortical network (functional connectivity) that is needed to perform a certain task was lower for persons with autism compared to matched controls.<sup>35</sup> Additionally, fMRI studies reported mirror neuron dysfunction as a possible explanation for the social and emotional deficits found in individuals with ASD. Mirror neurons are thought to be the neural mechanism that assists in understanding the actions, intentions, and emotions or internal experiences of another's emotions. For individuals with ASD, early mirror neuron dysfunction may mean that a lack of connections between neural systems leads to the inability to connect feelings to information.<sup>36</sup>

## Neurochemistry

Studies of neurochemistry are investigating a wide array of transmitter systems that may contribute to ASD. Most neurochemical studies of ASD are complicated by the co-morbidity or behavior problems associated with ASD, as well as small sample sizes and inappropriate control groups. These concerns make it difficult to extract confident solutions from research results. Although research of serotonin has been most promising, dopamine, acetylcholine, oxytocin, and amino acid neurotransmitters are among the neurochemicals being investigated with regard to the development and expression of ASD.

Among all neurochemical investigations in autism, serotonin (5-hydroxytryptamine or 5-HT) has stimulated the most research and investigation. Serotonin is an indolamine that is derived from the essential amino acid tryptophan. Serotonin regulates mood, eating, body temperature, arousal, pain sensitivity, and hormone release.<sup>37</sup> Evidence that acute depletion of the dietary precursor of serotonin (tryptophan) increases the symptoms of ASD is stimulating further research on serotonin.<sup>38</sup> It has also been proposed that high levels of serotonin during early development may create a loss of serotonin terminals and therefore hinders neuronal development.<sup>39</sup> Some

research has evidenced higher rates of ASD in children exposed to serotonin enhancing drugs in utero.<sup>40-41</sup> Selective serotonin reuptake inhibitors (SSRI's), including fluoxetine, paroxetine, and citalopram, have been reported to be the most prescribed psychotropic medications in autism, and are effective in managing preservative behaviors such as compulsions, stereotypies, and self-injury.<sup>42</sup>

Dopamine (DA) is a catecholamine that is synthesized from the dietary amino acid tyrosine. Dopamine function in the brain involves systems that contribute to movement control, emotion, stimuli reinforcement, memory, and higher-order functioning.<sup>43</sup> Dopamine blockers, such as anti-psychotics, have been observed to alleviate symptoms of ASD, such as hyperactivity, various stereotypical behaviors, aggression, and self-injury.<sup>44</sup>

Norepinephrine is a catecholamine with dual roles as a hormone and a neurotransmitter. As a stress hormone, norepinephrine affects parts of the brain where attention and responding actions are controlled. Along with epinephrine, norepinephrine also underlies the fight-or-flight response, directly increasing heart rate, triggering the release of glucose from energy stores, and increasing blood flow to skeletal muscles. Norepinephrine works in systems of the brain that play a critical role in attention, information and stimuli filtering, stress response, anxiety, and memory. Unfortunately evidence for the role of norepinephrine in the manifestation of ASD is inconsistent and insufficient.<sup>37</sup>

Acetylcholine (Ach) is the neurotransmitter found at the neuromuscular junction, in autonomic nervous system ganglia, and in multiple sites in the central nervous system.<sup>45</sup> Acetylcholine has functions both in the peripheral nervous system and in the central nervous systems as a neuromodulator. In the peripheral nervous system, acetylcholine activates muscles, and is a major neurotransmitter in the autonomic nervous system. In the central nervous system, acetylcholine and the associated neurons form a neurotransmitter system, the cholinergic system, which tends to cause excitatory actions. In the Acetylcholine has been implicated in development of the ability to focus on the environment and achieve a coherent behavior response.<sup>37</sup> Evidence has also shown that cognitive deficits typical in individuals with ASD may be influenced by a disruption in the cholinergic system,<sup>46-48</sup> especially in the basal forebrain region.<sup>49</sup>

Oxytocin (OT) is a peptide synthesized in the paraventricular nucleus (PVN) and the supraoptic nucleus (SON) in the brain. It is a mammalian hormone that also acts as a neurotransmitter in the brain. Cells in the PVN that synthesize oxytocin project diffusely throughout the brain and the brainstem.<sup>50</sup> It has also been found that receptors for oxytocin are located throughout the limbic system in the forebrain and in the autonomic centers in the brainstem.<sup>51</sup> Behaviorally, the OT system has been implicated in maternal behavior, infant separation distress, sexual behavior, and in the development of social attachments.<sup>52,53</sup> Given that social impairment is a primary symptom of autism, researchers have begun to investigate whether or not the OT system is dysfunctional in individuals with autism. Recent studies give preliminary suggestive evidence that oxytocin dysregulation may play a role in autism.<sup>54,55</sup>

Researchers Jane Yip, Adrian Oblak, and Gene Blatt<sup>56</sup> at Boston University School of Medicine have been examining the regulation of brain-derived neurotropic factor (BDNF) in the cerebellum of individuals with autism. BDNF is a protein found in the brain that plays a significant role in long-term neuronal development and survival. The levels of BDNF have been found to be significantly decreased in individuals with autism when compared to age matched controls. Reduced BDNF in the cerebellum may be an indicator of aberrant brain development and growth in autism. Italian researchers Lintas, Papeleo, Garbette, Mirnics, & Persico<sup>57</sup> have found increased or unusual patterns of methylation in regions of the brain as compared to matched. This was based on gray matter brain tissue samples of eleven autistic patients with age and sex matched controls.

## **Vision, Vision Information Processing and Autism**

There have been several empirical demonstrations of unusual visual abilities of individuals with autism. For example, individuals with autism have been found to be superior on embedded figure tasks<sup>58</sup> and block design tasks.<sup>59,60</sup> Other research has demonstrated that children and adults with autism do better on visual discrimination<sup>61</sup> and visual search tasks.<sup>62</sup>

Visual acuity and refractive error are often reported to be highly variable in individuals with autism. Snellen acuity, for instance, has been found to be variable in children with autism but this may be due to the many behaviors exhibited by the child with autism

that interfere with assessing acuity. The magnitude of refractive error has been found to be significant in up to 44% of individuals with autism.<sup>63</sup>

Anomalies of the binocular visual system such as strabismus can also be of concern. Intermittent strabismus has been found in children with autism with rates ranging from approximately 21% to 84% of the population studied.<sup>63</sup> Intermittent strabismus may add to the sensory confusion of those with autism because of the constantly changing visual input they would receive. We do not know if those with intermittent strabismus exhibit more environmentally adverse behaviors than those without this vision dysfunction.

Oculomotor findings, specifically pursuits and saccades, have been found to be deficient in individuals with ASD.<sup>64,65</sup> One study measured the voluntary, horizontal non-predictable saccades of 11 patients with autism spectrum disorders. Six of the 11 subjects had abnormal eye movements. Saccades were hypometric in six subjects and were of reduced velocity in four.<sup>64</sup> A second study by Rosenhall, Johanson and Gillberg in 1988 investigated pursuits and fixations found that 50% had poor pursuits and 78% had poor fixation.<sup>64</sup>

More recent research/assessments of the oculomotor system of those with autism note that saccadic abnormalities often associated with autism suggest a functional disturbance in the cerebellar vermis or its output through the fastigial nuclei. This tends to be consistent with a chronic cerebellar vermis lesion.<sup>66</sup> It has also been noted that when using visually guided saccades, individuals with autism had increased activation of the dorsolateral prefrontal cortex, caudate nucleus, medial thalamus, anterior and posterior cingulate cortex, and right dentate nucleus. This indicates that those systems, are often dedicated to cognitive control, may have to compensate for disturbances in lower-level visual motor systems and can result in the saccadic and pursuit abnormalities frequently seen in autism.<sup>67</sup>

A recent review by Trachtman<sup>68</sup> also noted that individuals within the spectrum of autistic disorders show many oculomotor anomalies that include a higher incidence of strabismus (more exotropia than esotropia) and saccades with significant undershooting and slow velocities. These children were also seen to have a wide range of refractive errors and visual acuities. Children with autism tend to demonstrate anomalous responses to the Optokinetic Nystagmus Drum Test as well. These abnormal OKN responses

may be due to the deficit in attentional behaviors often exhibited by children with autism.

Other researchers have shown significant anomalous responses to various electrophysiological tests such as the electroencephalogram (EEG), the electroretinogram (ERG) and various evoked potentials including the Visual Evoked Potential (VEP) and Auditory Evoked Potential (AEP). At least one or more researchers have stated that up to 80% of children with autism have anomalous EEGs, 49% abnormal ERGs, and that when VEP testing is completed an attenuated P300 wave was noted in many children with autism. The P300 wave is a component of evoked potential testing and is thought to be an indication of cognitive functioning.<sup>69</sup>

### **Can Autism Be Cured?**

It is somewhat preposterous to discuss a cure for any disorder when we do not know its etiology. We do know that the many signs and symptoms associated with autism can be treated. We do know that the result of this treatment can, in a positive manner, affect the quality of life for the individual with autism.<sup>69-71</sup> Although current research suggests that those diagnosed with ASD tend to maintain that diagnosis over time, a change of diagnosis for at least some children can occur. It has also been noted that with treatment, appropriate outcomes can be obtained that improve the child's quality of life especially for those individuals with higher cognitive ability and non-verbal intelligence.<sup>72</sup>

### **The Role of the Optometrist**

The doctor with experience in applying the concepts of behavioral, functional and developmental optometry to patient care should be an integral member of the diagnostic and treatment team for those suspected of having ASD. The optometrist's role should include the diagnosis and treatment of any ocular pathology, vision dysfunction, visual perception anomaly and refractive error present. As noted in this article, individuals with ASD have numerous neuro-anatomical, neurophysiological, neuropsychological, cognitive and other anomalies that can affect the oculomotor system, vision information processing/visual perception, and the development of refractive error that may require our intervention. Optometrists trained to work with those with developmental disabilities and the non-verbal patient need to assertively pursue seeking out these

special needs patients. Optometrists, schools and colleges of optometry, and professional organizations should support these efforts as well. <sup>74-77</sup>

## References

- Kanner L. Autistic disturbance of affective contact. *Nervous Child* 1943;(2):217-250.
- Wing L. The spectrum of autistic disorders. *Hospit Medici*:65(9):242-245.
- Centers for Disease Control and Prevention. Morbidity and mortality report. Volume 56. Atlanta: Coordinating Center for Health Information and Services, 2007.
- Moldin S, Rubenstein J, Hyman S. Can autism speak to neuroscience? *J of Neurosci* 2006;26:6893-6896.
- American Psychiatric Association. Diagnostic and statistical manual of mental disorders IV-TR. Washington, DC: American Psychiatric Association, 2000.
- Frith U. *Autism: Explaining the enigma*. Oxford: Blackwell Publishers Ltd., 1997.
- Cohen D, Volkmar F. *Autism and pervasive developmental disorders*, 2nd edition. New York: John Wiley & Sons, Inc. 1997.
- Brambilla P, Hardan A, Ucelli di Nemi S, Perez J, Soares J, Barele F. Brain anatomy and development in autism, review of structural MRI studies. *Brain Res Bulletin* 2003;61(6):557-569.
- Abell F, Krams M, Ashburner J, Passingham R, Friston K, et al. The neuroanatomy of autism: a voxel-based whole brain analysis of structural scans. *Neuroreport* 1999;10:1647-1651.
- Aylward EH, Minshew NJ, Goldstein G, Honeycutt NA, Augustine, AM, et al. MRI volumes of amygdale and hippocampus in non-mentally retarded autistic adolescents and adults. *Neurology* 1999;53:2145-2150.
- Howard MA, Cowell PE, Boucher J, Broks P, Mayes A. et al. Convergent neuroanatomical and behavioural evidence of amygdale hypothesis of autism. *Neuroreport* 2000;11:2931-2935.
- Brambilla P, Hardan A, Ucelli di Nemi S, Perez J, Soares J, Barele F. Brain anatomy and development in autism, review of structural MRI studies. *Brain Res Bulletin* 2003;61(6):557-569.
- Piven J, Nehme E, Simon J, Barta P, Pearlson G, Folstein S. Magnetic resonance imaging in autism: measurement of the cerebellum, pons, and fourth ventricle. *Biol Psychi* 1992;31:491-504.
- Elia M, Ferri R, Musumecia, S, Panerai S, Bottitta M, Scuderi C. Clinical correlates of brain morphometric features of subjects with low-functioning autistic disorder. *J Child Neuro* 2000;15:504-508.
- Hardan A, Minshew N, Keshavan M. Posterior fossa magnetic resonance imaging in autism. *J Amer Acad Child Adol Psychi* 2001;40:666-672.
- Adolphs R, Baron-Cohen S, Tranel D. Impaired recognition of social emotions following amygdale damage. *J Cog Neurosc* 2002;14:1264-1274.
- Bailey A, Luthert P, Bolton P, Le Couteur, A, Rutter, M, Harding B. Autism and megalencephaly. *Lancet* 1993;341:1225-1226.
- Girgis RR et al. Volumetric alterations of the orbitofrontal cortex in autism. *Prog Neuropsychopharmacol Bio Psychiatry* 2007 31(1):41-5.
- Hardan AY et al. Magnetic resonance imaging study of the orbitofrontal cortex in autism. *J Child Neuro* 2006 (10): 866-71.
- Carper R, Moses P, Tigue, Z, Courchesne E. Cerebral lobes in autism: early hyperplasia and abnormal age effects. *Neuroimage* 2002;16:1038-1051.
- Piven J, Arndt S, Bailey J, Anderasen N. Regional brain enlargement in autism: a magnetic resonance imaging study. *J Amer Acad Child Adol Psych* 1996;35:530-536.
- Courchesne E, Press G, Yeung-Courchesne, R. Parietal lobe abnormalities detected with MR in patients with infantile autism. *Amer J Roent* 1993;160(2):387-393.
- Haznedar M, Buchsbaum M, Wei T, Hof P, Cartwright C, et al. Limbic circuitry in patients with autism spectrum disorders studies with positron emission tomography and magnetic resonance imaging. *Amer J Psych* 2000;157:1994-2001.
- Saitoh O, Karns C, Courchesne E. Development of the hippocampal formation from 2 to 42 years: MRI evidence of smaller area dentate in autism. *Brain* 2001;124:1316-1324.
- Haznedar M, Buchsbaum M, Wei T, Hof P, Cartwright C, et al. Limbic circuitry in patients with autism spectrum disorders studies with positron emission tomography and magnetic resonance imaging. *Amer J Psych* 2000;157:1994-2001.
- Howard MA, Cowell PE, Boucher J, Broks P, Mayes A. et al. Convergent neuroanatomical and behavioural evidence of amygdale hypothesis of autism. *Neuroreport* 2000;11:2931-2935.
- Egass B, Courchesne E, Saitoh O. Reduced size of corpus callosum in autism. *Arch Neurol* 1995;52:794-801.
- Hardan A, Minshew N, Keshavan M. Corpus callosum size in autism. *Neurol* 2000;55:1033-1036.
- Manes F, Piven J, Vranici D, Nanclares V, Plebst C, Starkstein S. An MRI study of the corpus callosum and cerebellum in mentally retarded autistic individuals. *J Neuropsych Clin Neurosc* 1999;11:470-474.
- Howard MA, Cowell PE, Boucher J, Broks P, Mayes A. et al. Convergent neuroanatomical and behavioural evidence of amygdale hypothesis of autism. *Neuroreport* 2000;11:2931-2935.
- Critchley H, Daly E, Phillips, M, Brammer M, Bullmore E, Williams S. et al. Explicit and implicit neural mechanisms for processing of social information from facial expressions: a functional magnetic resonance imaging study. *Hum BrainMap* 2000;9:93-105.
- Courchesne E. New evidence of cerebellar and brain stem hypoplasia in autistic infants, children, and adolescents: the MR imaging study by Hashimoto and colleagues. *J Autism Dev Dis* 1995;25(1):19-22.
- Bailey A, Luthert P, Dean A, Harding B, Janota I, Montgomery M. A clinicopathological study of autism. *Brain* 1998;121:889-905.
- Howard Florey Institute. Autism problems explained in research. *Science Daily* 2005;October 26.
- Just M, Cherkassky V, Keller T, Minshew N. Cortical activation and synchronization during sentence comprehension in high-functioning autism: Evidence of underconnectivity. *Brain* 2004;127:1811-1821.
- Minshew N, Williams D. The new neurobiology of autism: Cortex, connectivity, and neuronal organization. *Neuro Rev* 2007;64:945-950.
- Lam K, Aman M, Arnold L. Neurochemical correlates of autistic disorders: A review of the literature. *Res Dev Dis* 2006;27:254-289.
- McDougle C, Naylor S, Cohen D, Volkmar F, et al. A double-blind placebo-controlled study of fluvoxamine in adults with autistic disorder. *Arch Gen Psychi* 1996;53, 1001-1008.
- Whitaker-Azmitia P. Serotonin and brain development: Role in human developmental diseases. *Brain Res Bulletin* 2001;56:479-485.
- Davis E, Fennoy I, Laraque D, Kanem, N. Autism and developmental abnormalities in children with perinatal cocaine exposure. *J Nat Med Asso* 1992;84:315-319.
- Kramer K, Azmitia E, Whitaker-Azmitia, P. In vitro release of [3H]5-hydroxytryptamine from fetal and maternal brain by drugs of abuse. *Brain Res Dev* 1994;78:142-146.
- Langworthy-Lam K, Aman M, Van Bourgondien M. Prevalence and patterns of use of psychoactive medicines in individuals with autism in the Autism Society of North Carolina. *J Child and Adol Psychopharm* 2002;12:311-322.
- Roberts P, Woodruff G, Iversen L. Dopamine. *Advances in biochemical psychopharmacology*, Vol. 19 New York: Raven Press, 1978.
- Young J, Kavanagh M, Anderson G, Shaywitz B, Cohen D. Clinical neurochemistry of autism and related disorders. *J Autism Devel Dis*:12:147-165.
- Kandel E, Schwartz J, Jessell T. (1995). *Essentials of neural science and behavior*. Norwalk, Connecticut: Appleton and Lange. 1995:296-297

46. Perry E, Lee M, Martin-Ruiz C, Court J, et al. Cholinergic activity in autism: Abnormalities in the cerebral cortex and basal forebrain. *Amer J Psychi* 2001;158:1058-1066.
47. Lee M, Martin-Ruiz C, Graham A, Court J, Jaros E, Perry R. Nicotinic receptor abnormalities in the cerebellar cortex in autism. *Brain* 2002;125:1483-1495.
48. Martin-Ruiz M, Lee M, Peery R, Baumann M, Court J, Perry E. Molecular analysis of nicotinic receptor expression in autism. *Mol Brain Res* 2004;123:81-90.
49. Bauman M, Kemper T. Neuroanatomic observations of the brain in autism. In M Bauman & T. Kemper (Eds.), *The neurobiology of autism*. Baltimore: The Johns Hopkins University Press. 1994:119-145.
50. Sofroniew V, Weindl A. Central nervous system distribution of vasopressin, oxytocin, and neurophysin. In J. Martinez, R. Jensen et al (Eds.) *Endogenous peptides and learning and memory processes*. New York: Academic Press. 1981:327-369.
51. Barberis, C., Tribollet, E. (1996). Vasopressin and oxytocin receptors in the central nervous system. *Critical Reviews in Neurobiology*, 10, 119-154.
52. Insel T, O'Brien D, Leckman J. Oxytocin, vasopressin, and autism: is there a connection? *Bio Psychi* 1999;45:145-157.
53. Insel T. Oxytocin: a neuropeptide for affiliation B evidence from behavioral, receptor autoradiographic, and comparative studies. *Psychoneuroendocrin* 1992;17:3-33.
54. Modahl C, Green L, Fein D, Morris M, Waterhouse L, Feinstein C. Plasma oxytocin levels in autistic children, *Bio Psychi* 1998;42:270-277.
55. Hollander E, Novotny S, Hanratty M, Yaffe R, et al. Oxytocin infusion reduces repetitive behaviors in adults with autistic and Asperger's disorders. *Neuropsychopharm* 2003;28:193-198.
56. Yip J, Oblak A, Blatt G. Decreased levels of brain derived neurotrophic factor (BDNF) in the cerebellum of patients with autism. *Society of Neuroscience Annual Conference*, San Diego 2007.
57. Lintas C, Papaleo K, Garbett K, et al. Reelin gene expression and promoter methylation status in temporal cortex of autistic brains. *Society of Neuroscience Annual Conference*, San Diego 2007.
58. Shah A, Frith U. An islet of ability in autism: a research note. *J Child Psych Psychi* 1983;24:613-620.
59. Rumsey J, Hamburger S. Neuropsychological findings in high functioning men with infantile autism, residual state. *J Clin Exp Neuropsych* 1998;10:201-221.
60. Shah A, Frith U. Why do autistic individuals show superior performance on the block design test? *J Child Psych Psychi* 1993;34:1351-1364.
61. Plaisted K, O'Riordan M, Baron-Cohen S. Enhanced discrimination of novel, highly similar stimuli by adults with autism during a perceptual learning task. *J Child Psych Psychi* 1998;39:765-775.
62. O'Riordan M, Plaisted K, Driver J, Baron-Cohen S. Superior visual search in autism. *J Exp Psych Hum Percept Perf* 2001;27(3):719-730.
63. Scharre J, Creedon M. Assessment of visual function in autistic children. *Optom Vis Sci* 1994;69(6), 433-439.
64. Rosenthal U, Johansson E, Gillberg C. Oculomotor findings in autistic children. *J Laryn Otol* 1988;102(5):435-439.
65. Kemmer C, Verbaten M., Cuperus J. Abnormal saccadic eye movements in autistic children. *J Autism Dev Dis* 1998;28(1):61-67.
66. Takarae Y, Minshew NJ, Luna B, Sweeney JA. Oculomotor abnormalities parallel cerebellar histopathology in autism. *J Neurol Neurosurg Psychiat*. 2004;75:1359-1361.
67. Takarae Y, Minshew NJ, Luna B, Sweeney JA. A typical involvement of frontostriatal systems during sensorimotor control in autism. *Psychiat Res Neuroimaging*. 2007 (57)2:117-127.
68. Trachtman JN. Background and history of autism in relation to vision care. *Optometry* 2008;79:391-396.
69. Grandin T. *Thinking in pictures: Expanded edition*. Vintage Books, NY, NY. 2006.
70. Grandin T, Barron S. *The unwritten rules of social relationships: decoding social mysteries through the unique perspectives of autism*. Future Horizons, Arlington, TX 2005.
71. Grandin T. *The way I see it. A personal look at autism & asperger's*. Future Horizons, Arlington, TX 2008.
72. Pandey J, Wilson L, Verbalis A, Fein D. Can autism resolve? In *Autism Frontiers*, Shapiro BK, Accardo PJ (eds). Paul H Brookes Pub. Baltimore, MD. 2008:191-205.
73. Sands W, Taub M, Maino D. Limited research and education on special populations in optometry and ophthalmology. *Optom Vis Dev* 2008;39(2):60-61
74. Maino D. Overview of special populations. In Scheiman M, Rouse M. (eds) *Optometric management of learning related vision problems*. St. Louis, MO: Mosby Inc. 2006;85-106.
75. Maino D, Steele G, Tahir S, Sajja R. Attitudes of optometry students toward individuals with disabilities. *Optom Ed* 2002;27(2): 45-50.
76. Maino D (ed). *Diagnosis and Management of Special Populations*. Mosby-Yearbook Inc St. Louis, MO. 1995. Reprinted *Optometric Education Program Foundation*, Santa Anna, CA. 2001.
77. Maino D. The young child with developmental disabilities: An introduction to mental retardation and genetic syndromes. In Moore BD (ed) *Eye care for infants and young children*. Butterworth-Heinemann, Newton, MA.1997:285-300.